

# Pouch Surgery

## A surgeon's perspective

Ms Jane Hughes  
Colorectal Surgical Registrar

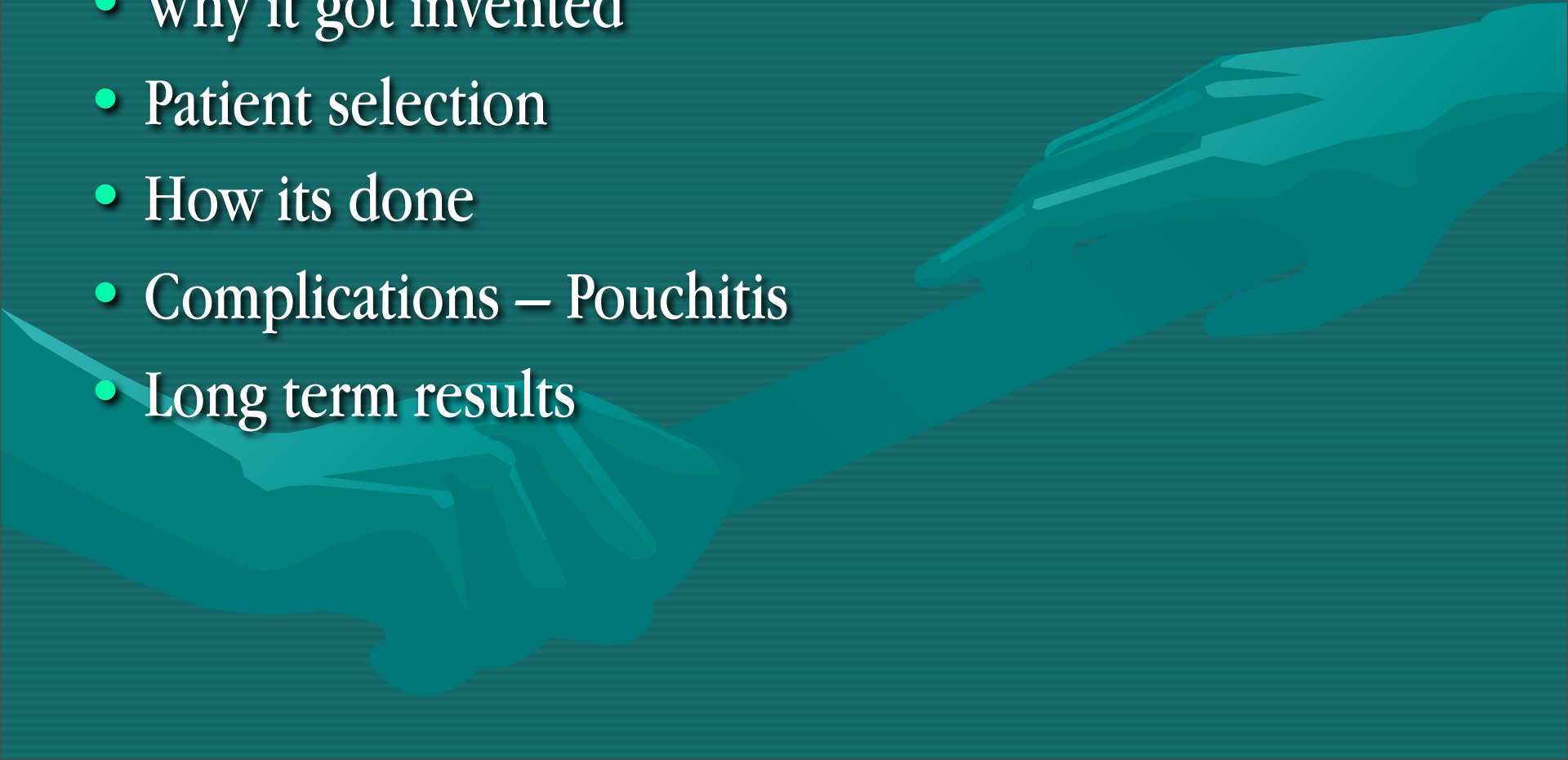
Good Morning

I am.....

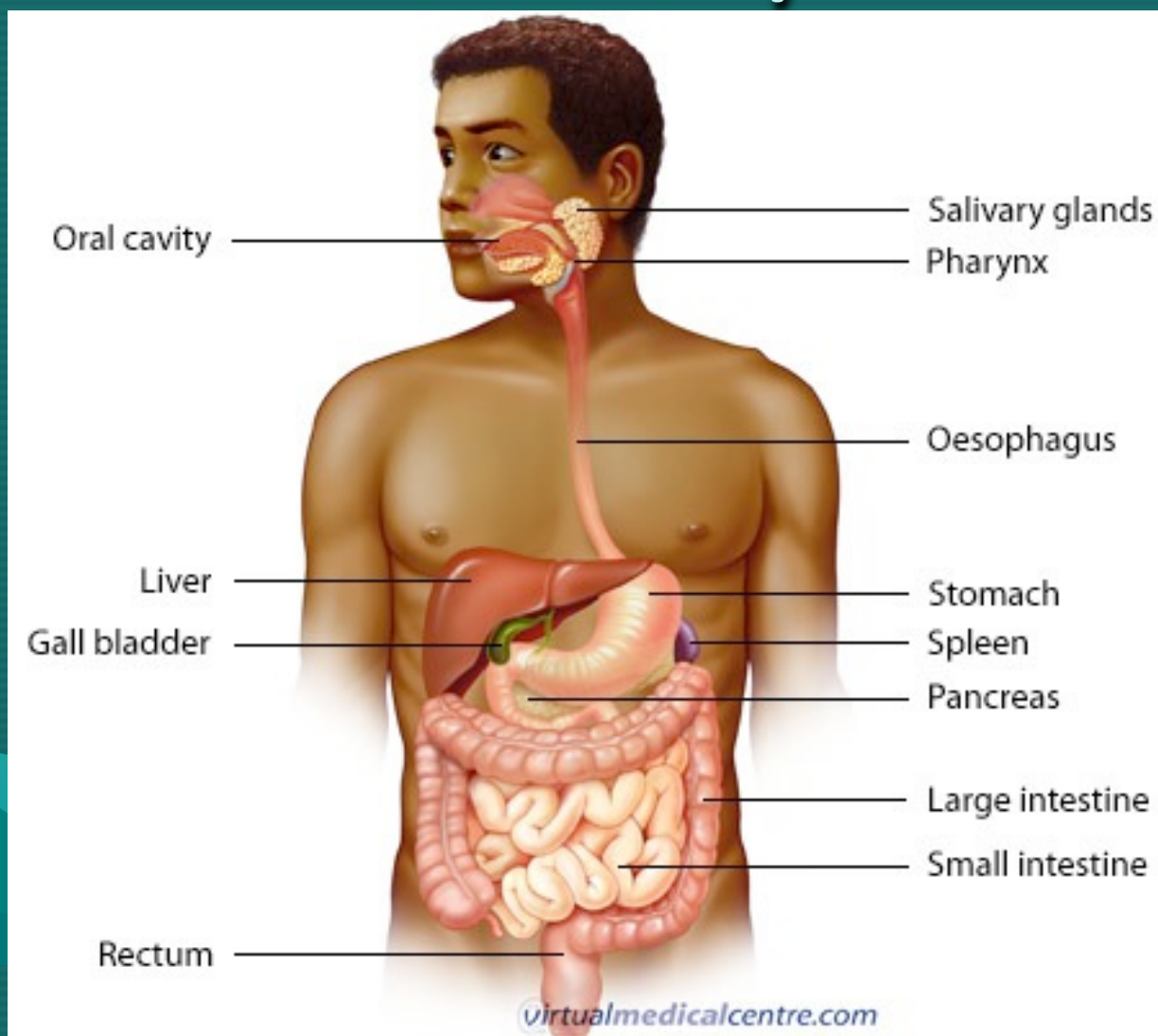
Any questions not answered today can be forwarded to my works address that i have placed at the end of the presentation

# Discussion Points

- Anatomy
- Why it got invented
- Patient selection
- How its done
- Complications – Pouchitis
- Long term results



# Anatomy



Back to basics I know but so we all set off from the same starting point i have included this simple diagram to show the normal anatomy of the gastro intestinal tract.

Mouth

Oesophagus

Stomach

Small Bowel – Average size 7 metres. most of the digestion and absorption of nutrients and fluid take place

Rectum – About 8inches long & acts as a Reservoir

Anal Canal with sphincters – Preserve Continence.

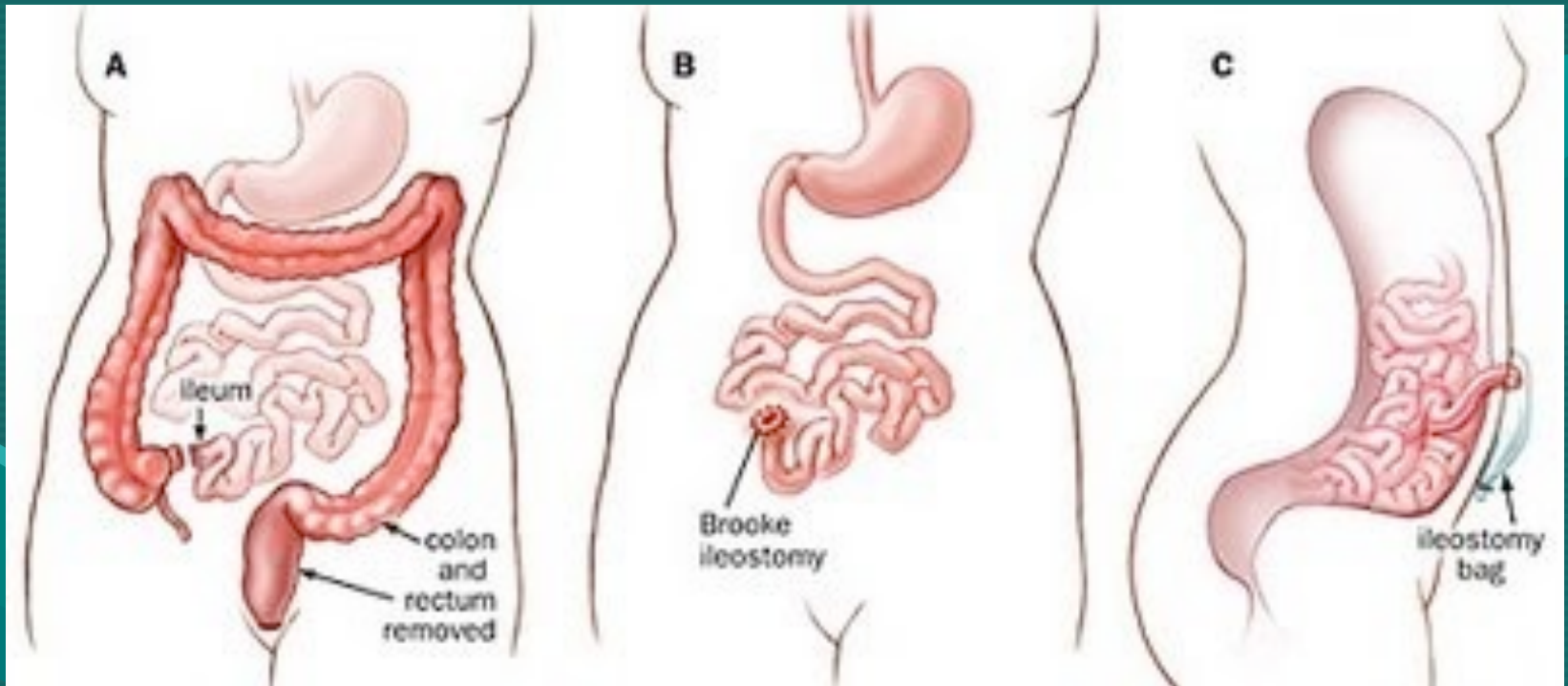
# Why did the pouch get invented? The problem?

- The surgical procedure for forming an ileo-anal pouch was developed as an alternative to the [ileostomy](#)

While most people adjust well to an ileostomy, a small proportion of patients find the change in body image and the psychological implications unacceptable.

Consequently surgeons endeavoured to find an alternative

# Permanent Ileostomy



Traditionally patients requiring proctocolectomy had a permanent ileostomy

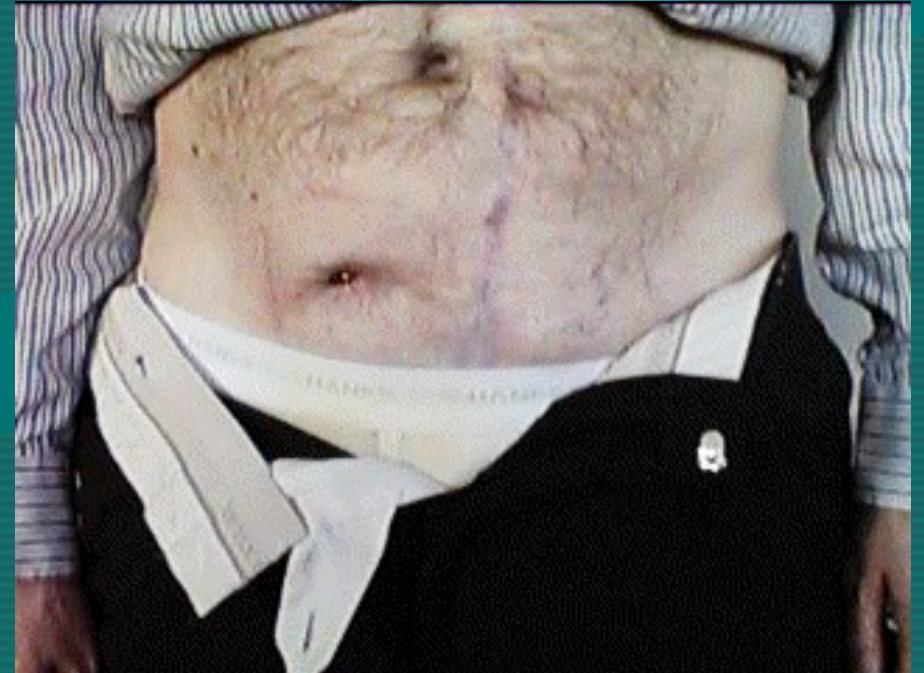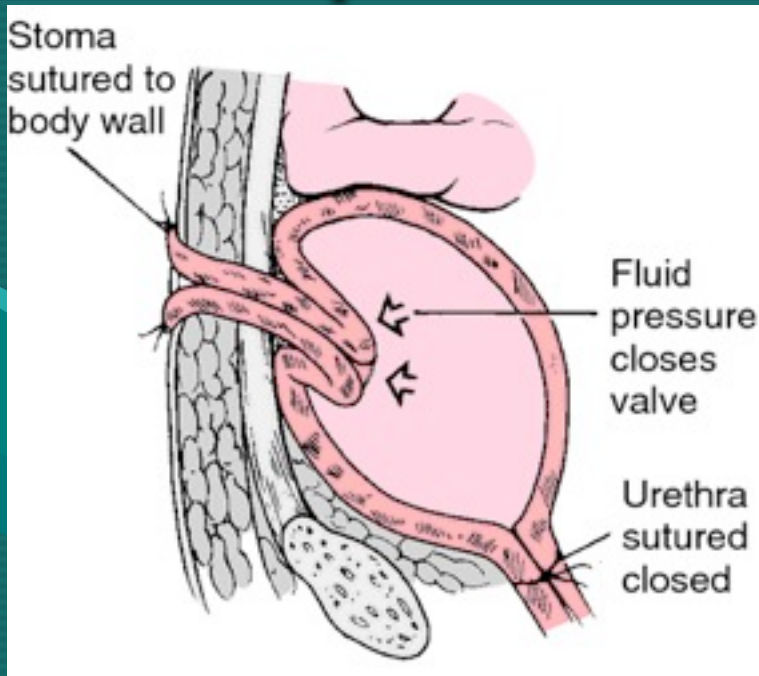
Eg

Familial Adenomatous Polyposis

Ulcerative Colitis

# An alternative to an ileostomy

- Ileorectal/ Ileoanal anastomosis
- The Kock pouch – continent ileostomy



Ileorectal / ileoanal anastomosis works well in children and is still often used. And...

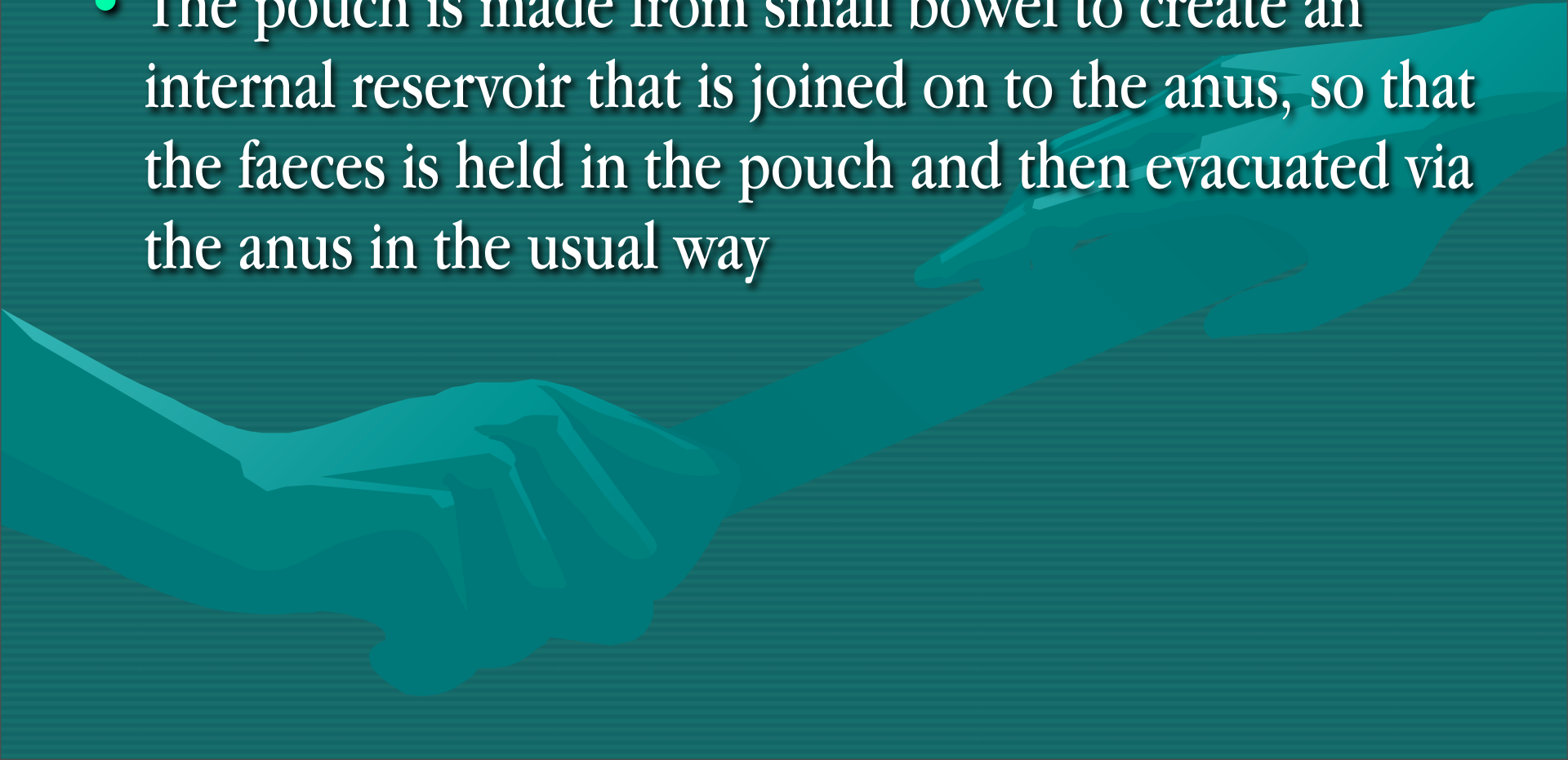
Previously a direct anastomosis between ileum & anal canal or low rectum had been used but this resulted frequently in frequency, urgency and incontinence problems.

The Kock pouch consists of a reservoir constructed from the small intestine, and a nipple valve which keeps the contents of the reservoir inside the body, and permits entry of an external catheter to drain the pouch when desired.

The catheter is a simple hollow plastic tube. It is inserted about 5 inches into the stoma, and the contents of the reservoir come out on their own. Immediately after surgery the pouch is emptied about every three hours, because the reservoir is small. But following the surgery it grows in size until it can be emptied only 3 or 4 times a day, approximately 2 months after surgery. In the absence of late night meals, it is rare to have to get up at night to empty.

# The Answer?

- The pouch is made from small bowel to create an internal reservoir that is joined on to the anus, so that the faeces is held in the pouch and then evacuated via the anus in the usual way



# Parks, Sir Alan Guyatt (1920 - 1982)

- This work was pioneered by [Sir Alan Parks](#) at St. Mark's Hospital in London in the early 1980s, the pouch was known as Parks' Pouch.



In 1978 Sir Alan Parks created the restorative proctocolectomy and was a revolutionary step.

Uses the ideas of the Kock Pouch and ileoanal anastomosis.

Not only does it allow continuity of the Gi tract and loss of the ileostomy it also allows continent anal function through preservation of the anal sphincters

However complications with the first types of pouches with incontinence AND PAIN ETC

# Japanese perfection Mr Utsunamiya



Mr Utsunamiya rarely credited although he perfected the technique as what we use today

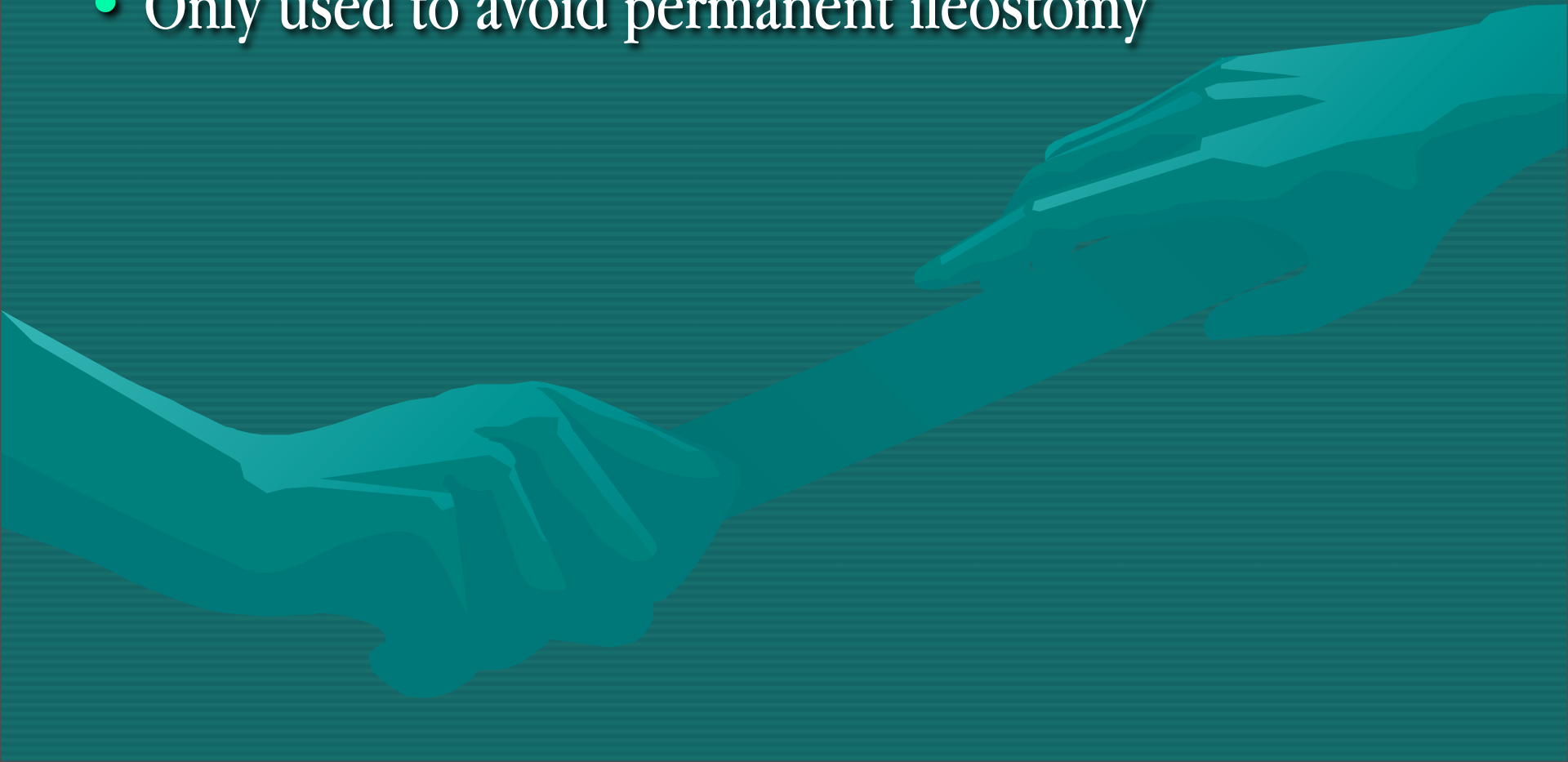
# Parks pouch also called:

- The Ileal Pouch-Anal Anastomosis (IPAA)
- Ileo-anal pouch
- Restorative proctocolectomy with ileal reservoir
- Ileal-anal pull through
- J-pouch, S-pouch or W-pouch

There have been a number of adaptations of the surgical technique of the pouch but all with the same intention.

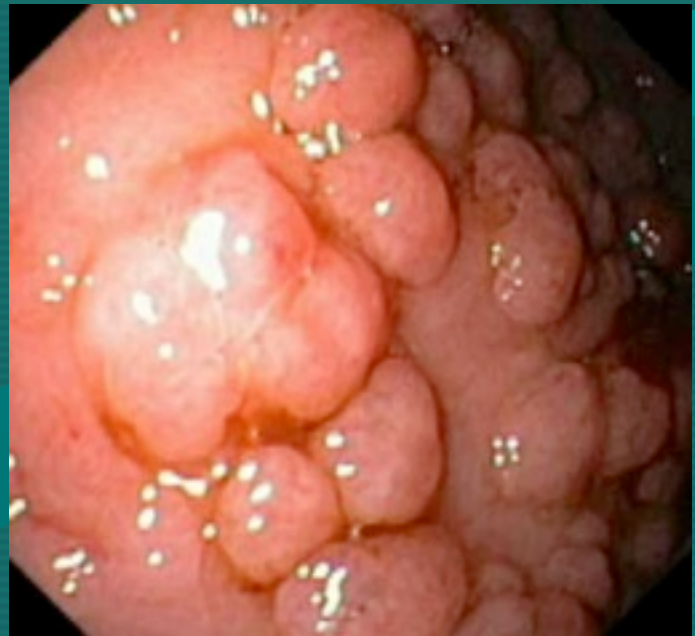
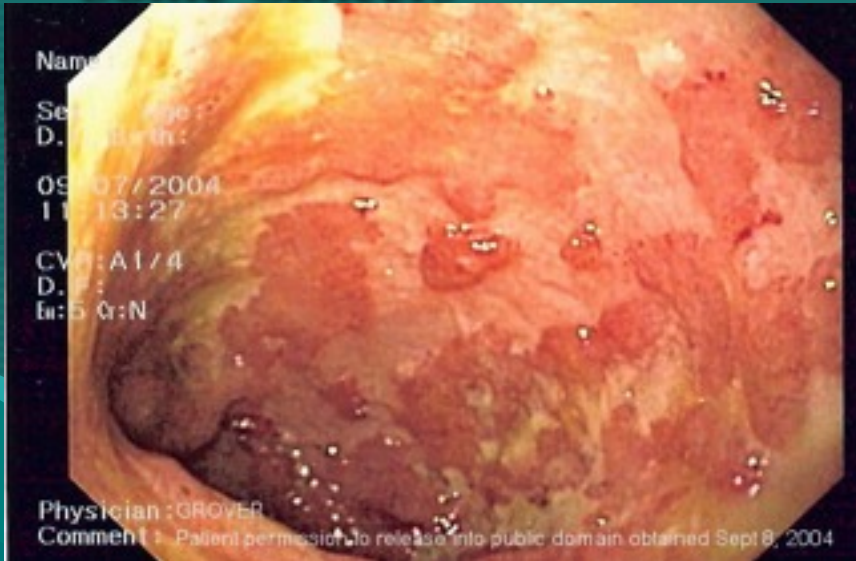
# Indications

- Only used to avoid permanent ileostomy



# Patient Selection

- Gold standard operation offered for
  - Ulcerative colitis
  - Familial Adenomatous Polyposis
  - Some Cancers



- Ensuring general health, cancer cure & adequate anal sphincter

Virtually all patients with pouches have one of two conditions:

ulcerative colitis (UC)

familial adenomatous polyposis (FAP)

# Contensious issues (1) Age

- Fertility in females is reduced and careful counselling of patient is essential
- Incontinence, usually minor, is more common in patients over 45 years old
  - No absolute contraindication in older patients
  - Assessment on individual basis, particularly regarding sphincter function.

Female fertility is reduced by almost 50% following restorative proctocolectomy. careful counselling of patient is essential

It appears that the pelvic dissection is the factor responsible

Young females may wish to have ileostomy and preservation of fertility and leave the restorative proctocolectomy for a later date.

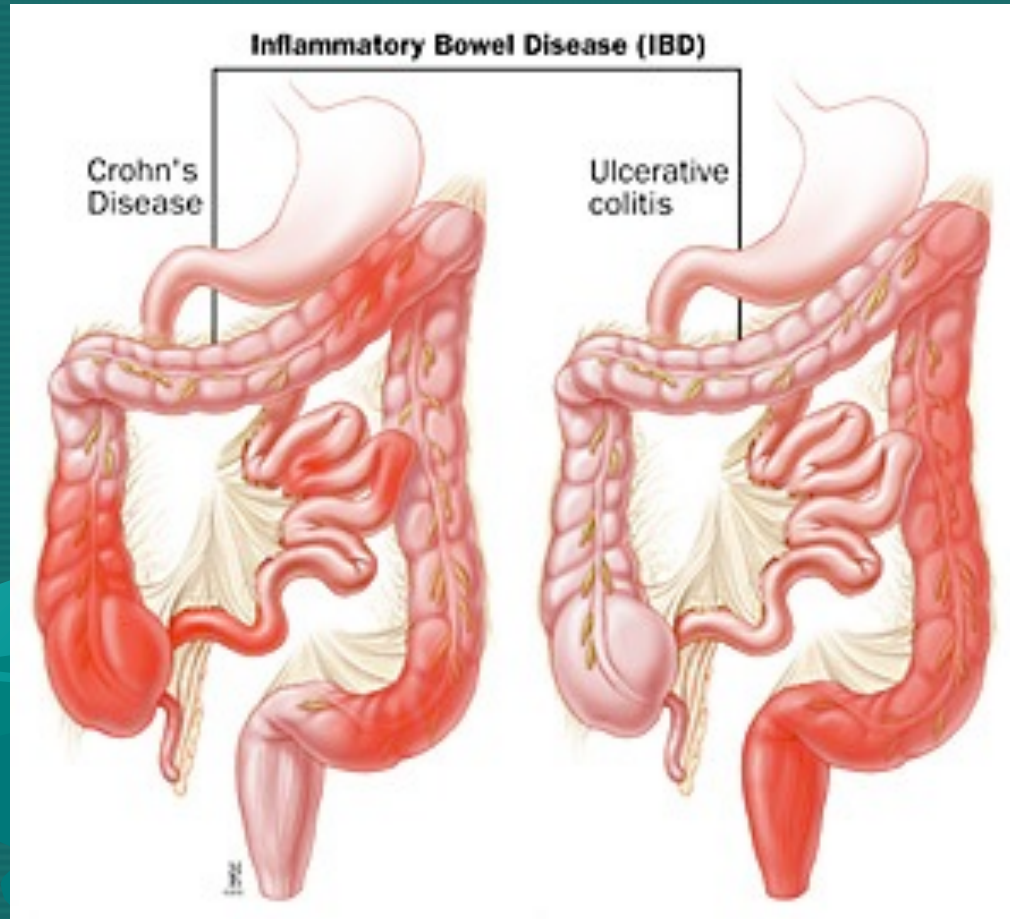
Incontinence, usually minor, is more common in patients over 45 years old

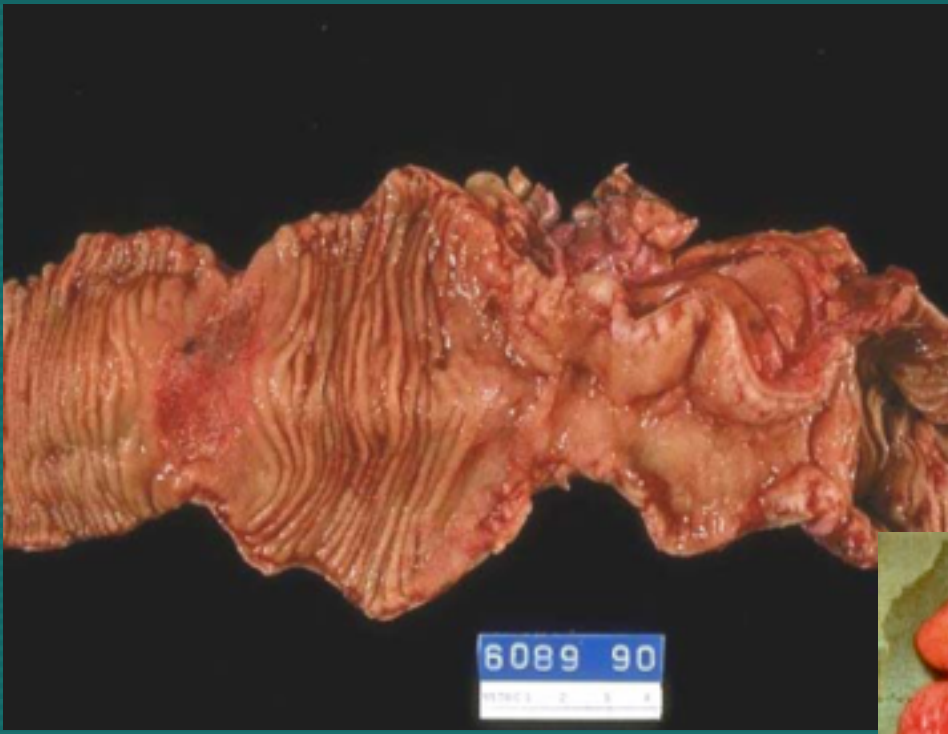
No absolute contraindication in older patients although there is a general consensus of a cut off of around 60 yrs old. - at this age more comorbidities, mobility issues and anal pathology leading to weak sphincters (esp in females)

Assessment on individual basis, particularly regarding sphincter function.

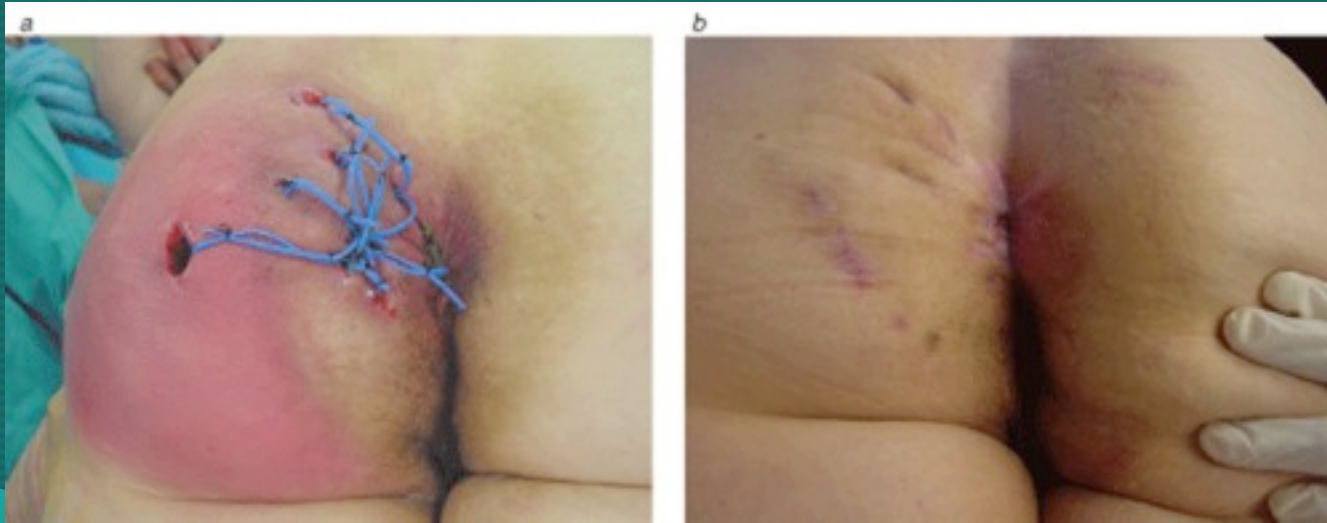
# Contentious issue (2) Crohns disease

## Crohns -v- Ulcerative Colitis





# Crohns and perianal disease



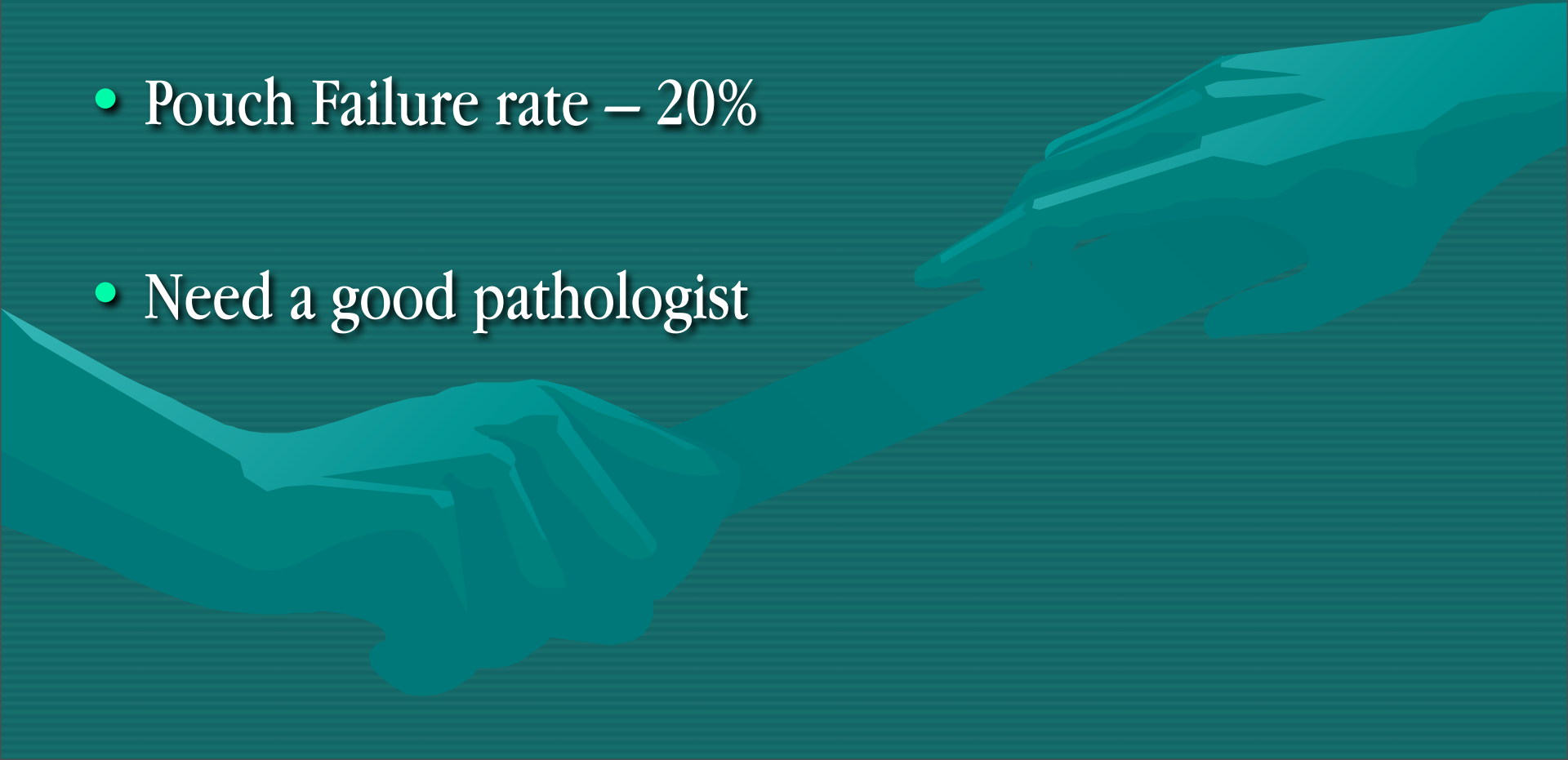# Contentious issues (2) Crohn's disease

- Much higher pouch failure rate
- Deemed as a contra indication
- However there are a small group of patients with large bowel crohns disease whom have small bowel and rectal sparing.

Where failure is defined as removal of a pouch and permanent ileostomy formed. = 50% for crohns

# Indeterminate Colitis

- 20% of all inflammatory bowel disease
- Pouch Failure rate – 20%
- Need a good pathologist

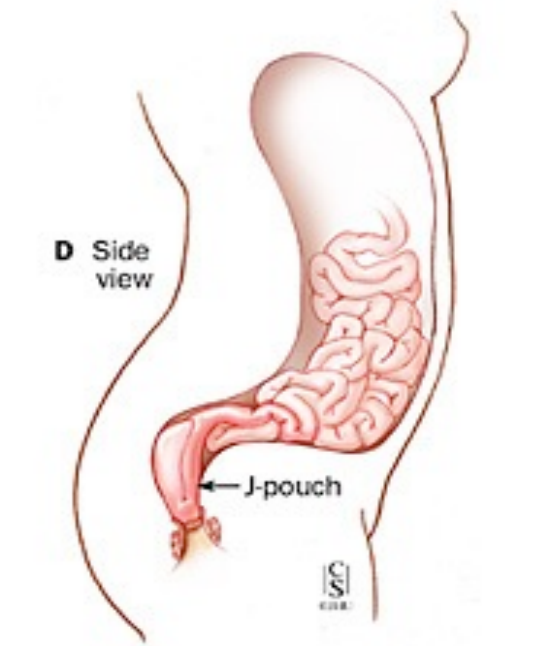
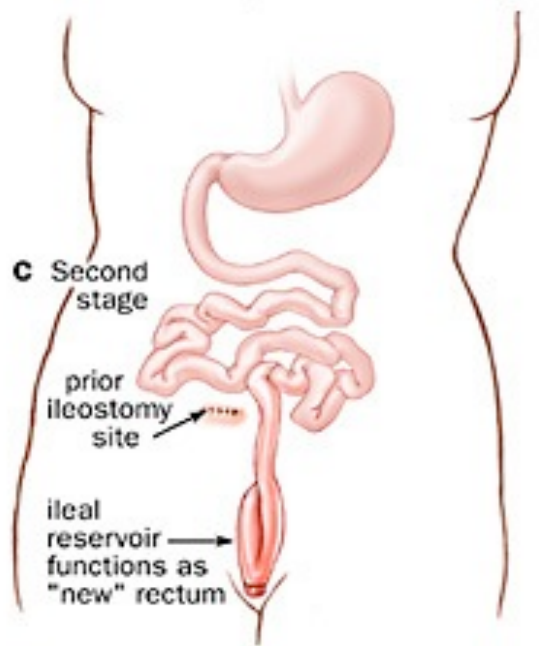
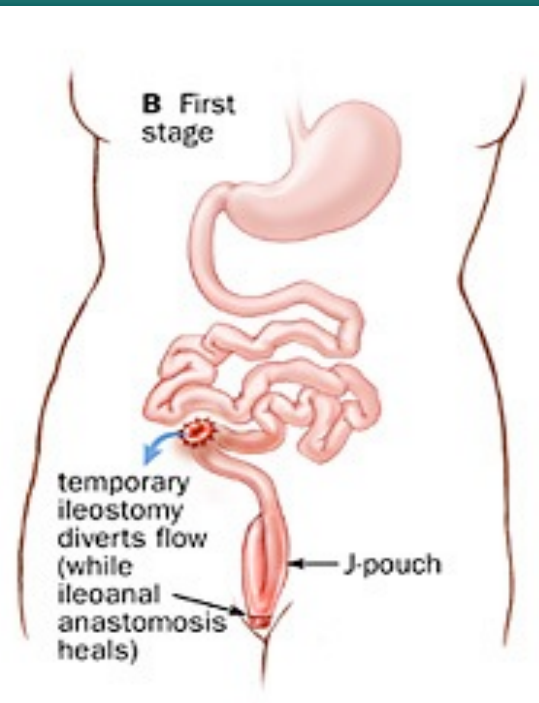
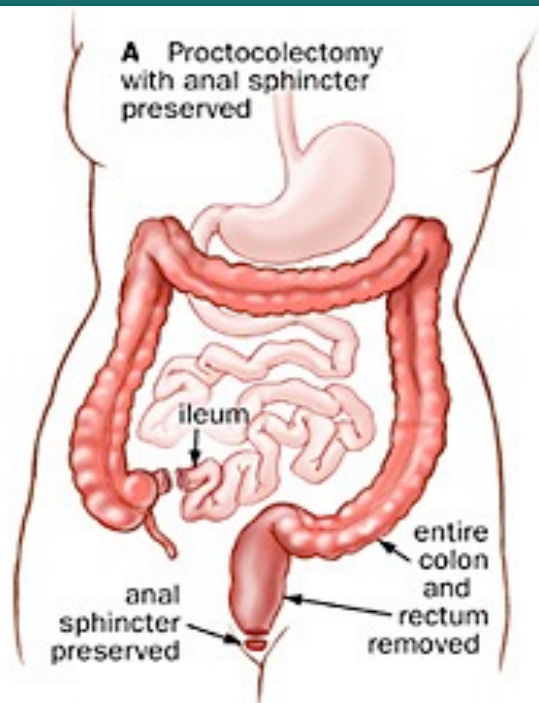


# Previous Anal Pathology

- History of anal pathology may indicate Crohn's disease.
- Presence of anal lesion increases risk of anastomotic leak
- Anal disease increases risk of pouch-perineal fistulas and subsequent failure

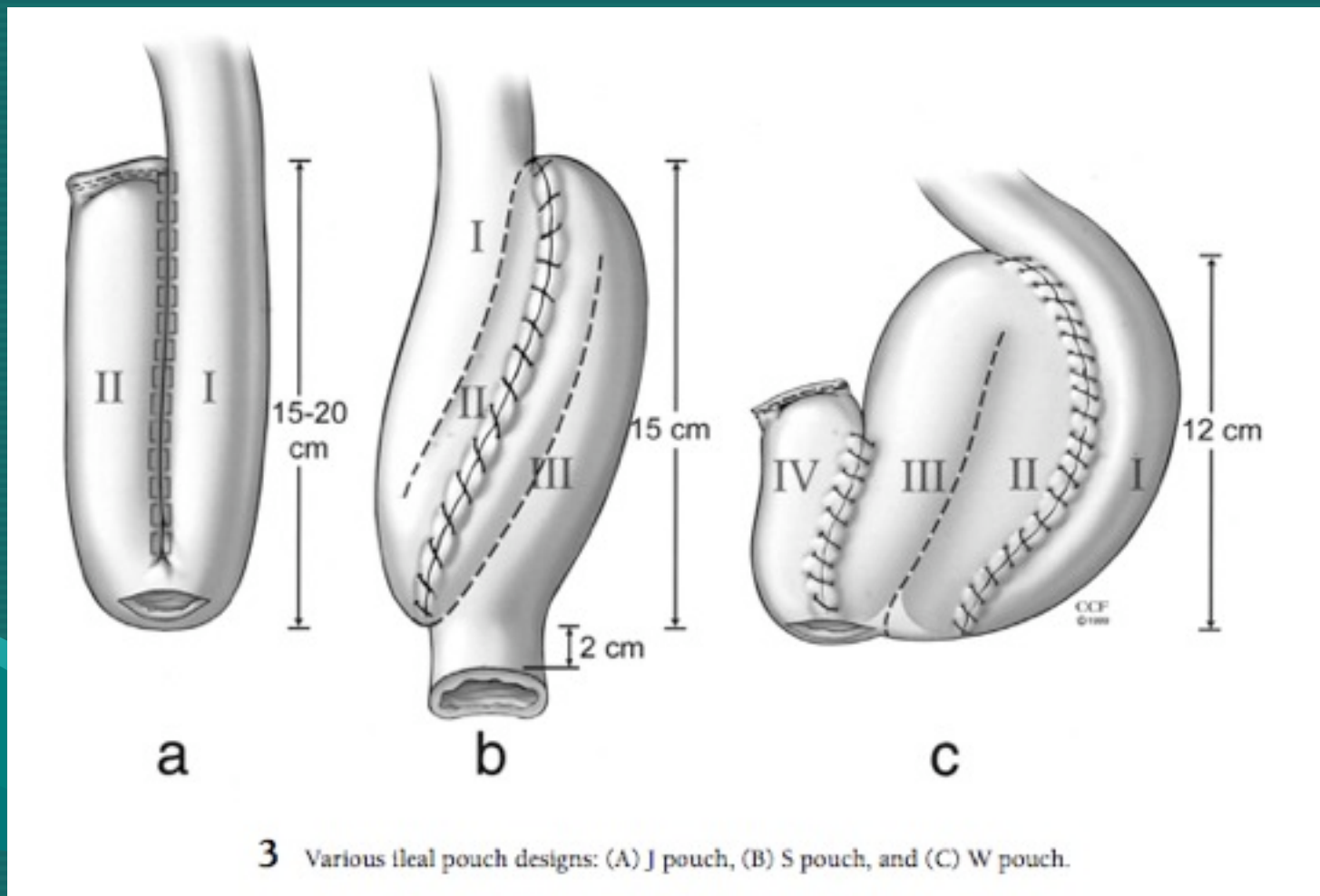
# How its done

- Excision of colon & rectum
- Preservation of anal canal and sphincters
- Creation of the pouch
- Can be done in 1 stage but usually done in 2 or 3 stages to avoid complications



C  
S  
©

# Construction of the Pouch

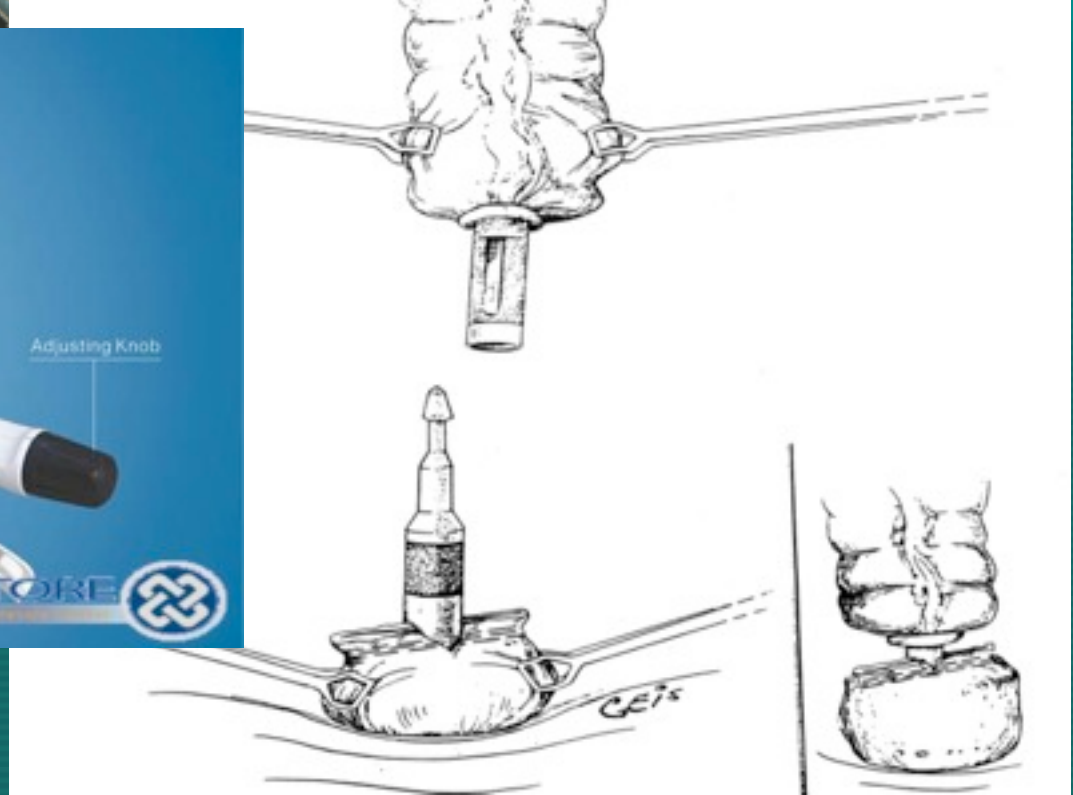
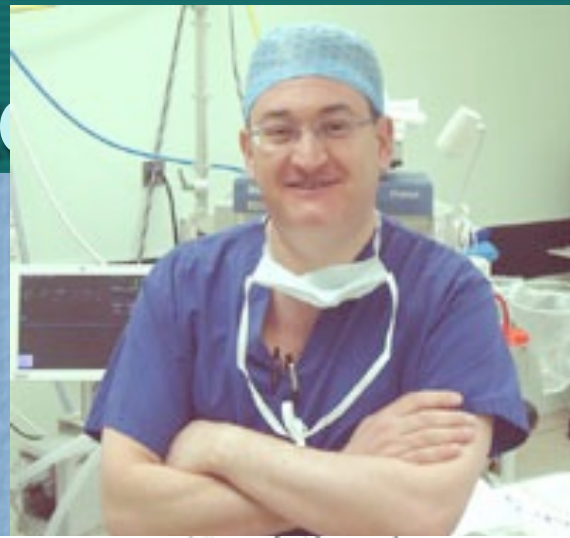

## How is a pouch made?

Basically pouches are made by opening lengths of small bowel to produce 'strips', and then joining these 'strips' together to form a bag. In the early days a number of different designs of pouch were tried, all made from different numbers of 'strips' joined together in different ways. The commonest of these were J, S and W pouches. Almost all pouches made nowadays are J pouches. W pouches are a little bit bigger, so may hold more faeces, requiring less frequent visits to the toilet, but sometimes they do not empty efficiently, and more bowel is needed to make them.

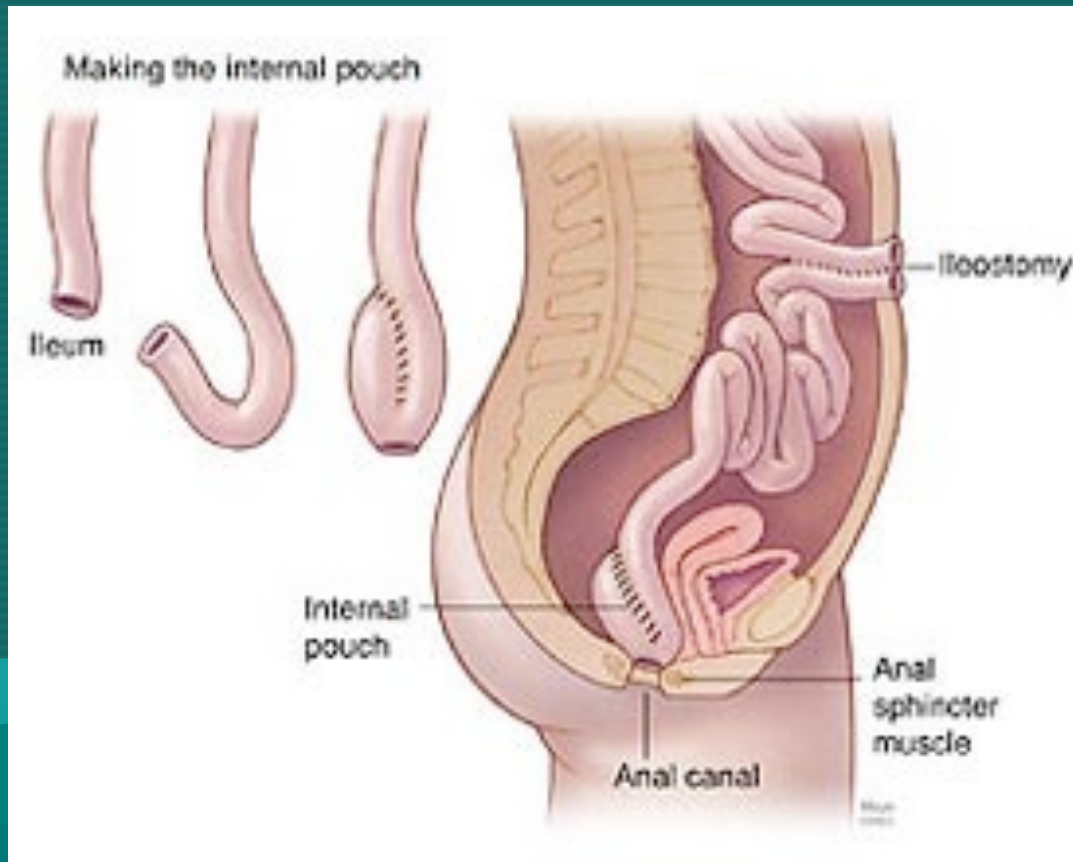
The 'strips' of bowel used to make the pouch were originally sewn together by hand, but usually special staplers are used now. The staples are made of a titanium alloy, so they do not rust, and do not set off airport metal detectors or cause problems with MRI scanners! They can be seen on X-rays though.

# The Anast



Handsewn – 2 consultant surgeons, 8hrs

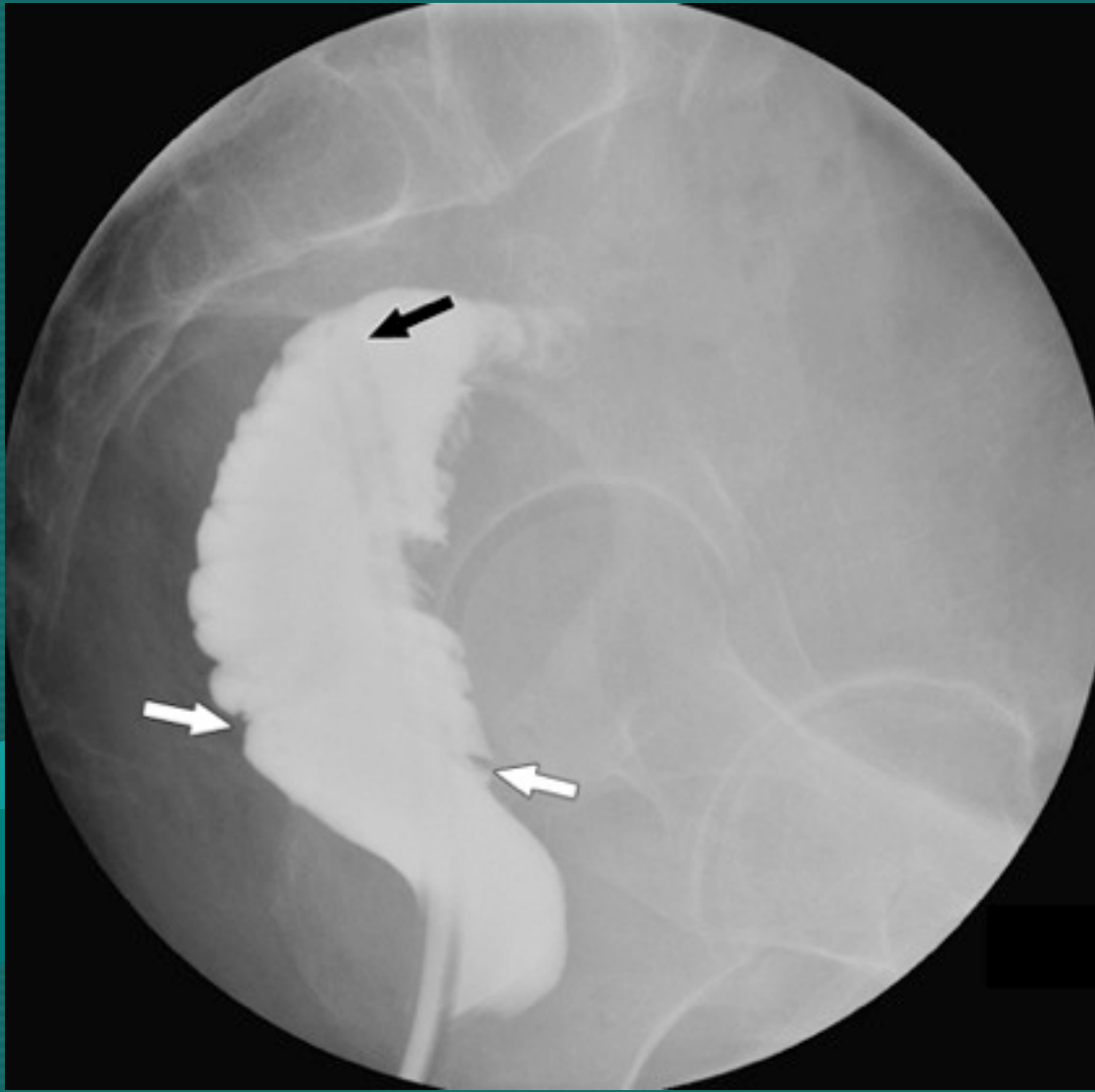
# J-pouch with temporary ileostomy



The pouch can be joined to the anus (anastomosis) either by hand stitching or using a special circular stapler. Hand stitching is difficult, and the anus is stretched and can be damaged when it is done. Stapling is more straightforward, but sometimes it is necessary to make the join very low down in the anus, where it has to be hand-sewn.

Usually after a pouch has been made a temporary loop ileostomy is formed upstream of it to allow all the various joins to heal before the pouch is used. Usually the pouch is tested to check for leaks after 6-12 weeks, before the ileostomy is closed. This is done using a pouchogram:

# Pouchogram



Here is a pouchogram: the pouch is filled with X-ray dye passed in through a catheter placed into the pouch through the anus, then several X-rays are taken over a few minutes

# Complications - General

- Bleeding
- Thrombosis
- Infections
- Adhesions
- Injury to pelvic nerves
  - impotence/ problems with erection or ejaculation

## What can go wrong?

Any operation carries risks, such as

Bleeding – requiring a blood transfusion

Thrombosis (clots) in the veins of the legs

chest infections or wound infections

In the longer term anyone who has had extensive abdominal surgery will have adhesions (scarring which sticks loops of bowel together), which can cause episodes of obstruction (blockage). In most cases this settles down of its own accord, but sometimes surgery is needed to unkink the bowel.

The pelvic surgery required to remove the rectum can be difficult and involves operating close to the ureters (tubes which drain urine from the kidneys into the bladder) and the nerves which allow erection and ejaculation in men. The risk of damaging these is small (1-5% risk of impotence) and is really a risk of removing the rectum, rather than of pouch surgery itself.

# Complications - Specific

- It doesn't reach!
- Pelvic Sepsis
  - Anastomotic leak/ Infected haematoma
- Anastomotic Stricture
- Pouchitis
- Polyps
- Fertility
- Cancer

## It doesn't reach – not enough length of small bowel – normal anatomy or previous surgery

**Anastomotic Leak** - The most serious problem is leakage from one of the seams (usually between the pouch and the anus). An ileostomy protects from the worst effects of leakage, but an abscess can form outside the pouch. Sometimes this can be successfully drained and the hole in the seam can heal. This does not always happen though, and chronic inflammation can result in a scarred pouch which will never work well.

**Anastomotic Stricture** - Sometimes the join between the pouch and the anus narrows down (a stricture or stenosis) so that the pouch cannot empty properly (5-20%). This may require stretching under anaesthetic, and then regular use of dilators to keep the anastomosis open.

**Pouchitis** - About 30% of people with pouches for UC develop inflammation of the pouch (pouchitis) at some time. We do not understand why this happens, but in most cases it can be easily treated with a course of antibiotics and does not return. A few people have troublesome recurrent pouchitis.

**Polyps** - Pouches made for FAP can develop polyps, so we follow this group of patients up very carefully and remove any large or worrying polyps.

**Fertility** - Research done over the last five years has shown that women who have had pouch surgery may have difficulty getting pregnant. This is likely to be due to adhesions forming around the Fallopian tubes, and is actually probably a result of removal of the rectum rather than pouch formation. We are now trying to avoid the pouch procedure in young women, postponing it until they have completed their families if at all possible. If a woman with a pouch is having trouble getting pregnant we suggest IVF treatment.

**Cancer** – when performing the anastomosis – a cuff of mucosa is left behind @the transitional zone' and colorectal cancers can form here. These can get cancers in them. Large debates globally and end result not at increased compared to general population. Same cuff that can cause cuffitis

# Pouchitis

- Clinical Condition diagnosed by
  1. Change in bowel function
  2. Evidence of active inflammation
  3. Evidence of a systemic response to inflammation
- 20-30% of patients with UC (not F.A.P)
- Cause?
- Treatment

Abnormal response to bacteria

Increased bacterial load.

Treated with antibiotics, antiinflammatories, steroids, Probiotics Treatment of pouchitis is with antibiotics and anti inflammatories

Probiotics have been shown to be effective in 85% of cases

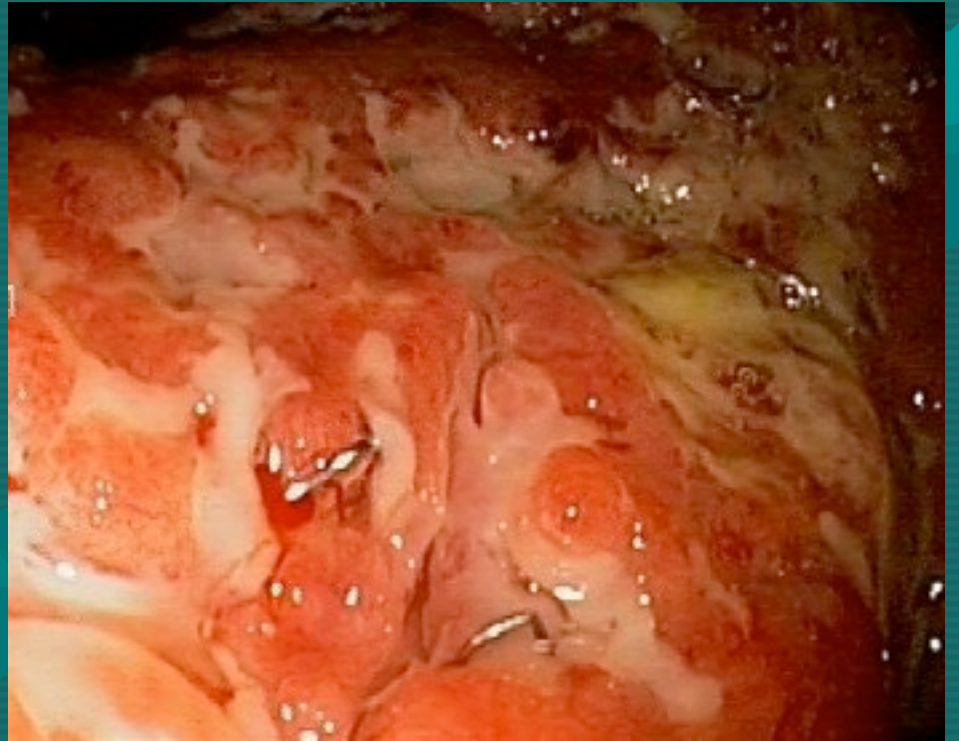
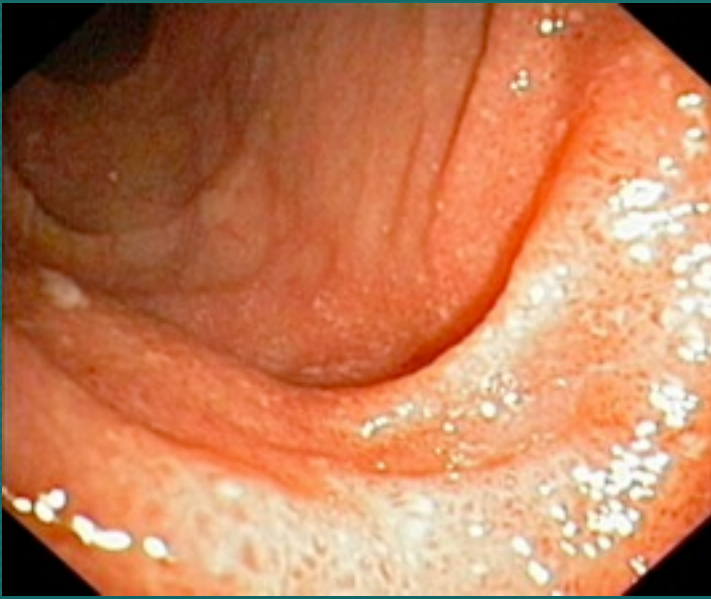
oral and enema

Pouchitis- acute inflammation associated with symptoms of frequency, urgency, liquid stool

Cause unknown but may be related to original disease as it occurs in UC but rare in FAP

Chronic proctitis – occurs in about 5% of all restorative proctocolectomy

# Pouchitis



# Living with a pouch

- Frequency of defecation - ranges from a median of 4 to 7 x in 24hrs.
- Urgency is present in only 5% of patients
- Anti diarrhoeals needed in upto 50% of cases
- Incontinence is rare – 5%
- Overall function improves with time

On average someone with an ileoanal pouch will need to go to the toilet five times per day and once at night. There may be some mucus leakage.

20 – 30% have a frequency of 8 or more acceptable

As this is an average, some people will empty their pouches less often than this, and others will go more frequently. Codeine or Loperamide can help to slow things down.

Over many years function seems to improve a little.

Some people have more difficult problems with continence, due to a combination of anal muscle weakness or damage, the loose faeces which are normal with a pouch and advancing age. Just occasionally an ileostomy is needed in these cases.

# Long Term

- In the absence of chronic complications, general health is good
- Deficiencies in iron & Vit B12 occur in <10%
- Such deficiencies can lead to anaemia
- Pouchitis (acute relapsing -v- chronic)
  - Concerns about dysplasia & therefore long term surveillance is essential

Long term surveillance by endoscopy with multiple biopsies at 5 yrs is recommended

Removal of pouch for pouchitis is rare – 1 -2%

Endoscopic surveillance every 1 – 2 yrs

# Long term success of the Pouch

- Overall about 90% of pouches are a success, and 10% fail.
- In some cases a new pouch can be made, but the failure rate of 'redo' pouches is considerably higher than those done for the first time.

Overall at 10 years post creation of pouch....about 90% of pouches are a success, and 10% fail, and this is usually because of leakage and infection or severe pouchitis.

# Summary

- The ileoanal pouch is an alternative to a permanent ileostomy
- Gold standard treatment for patients post panproctocolectomy for UC or FAP (not Crohn's)
- Think about fertility & sexual function
- First introduced in 1972 – Now usually J shaped
- Usually 2 or 3 stage procedure
- Common complications – pouchitis
- Pouch function & long term results

# Any Questions?

[Jane.Hughes@srft.nhs.uk](mailto:Jane.Hughes@srft.nhs.uk)

